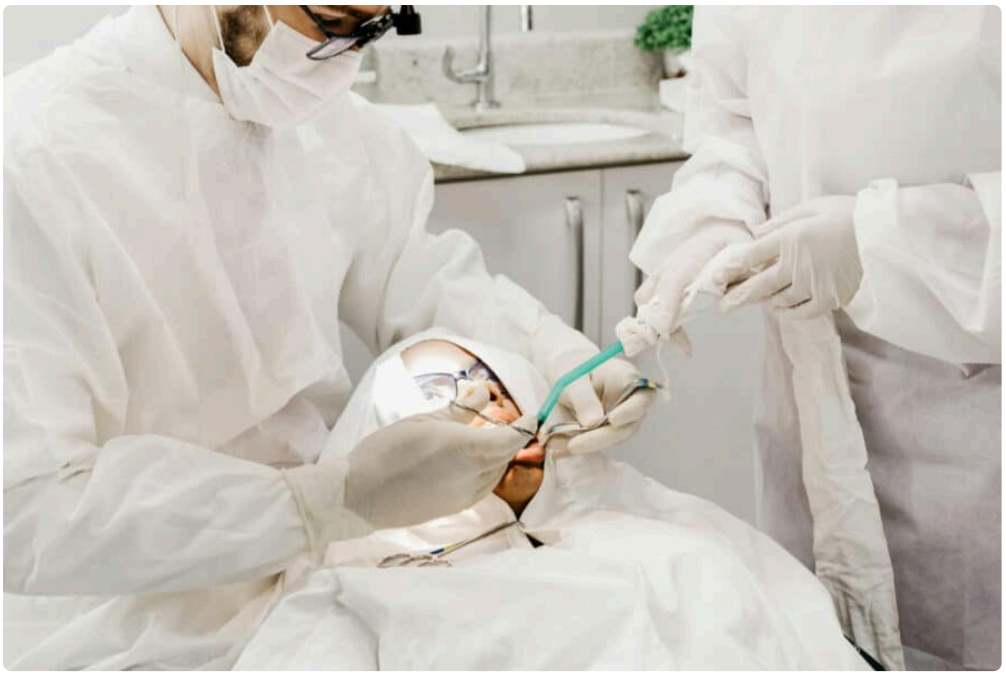

Severe tooth decay rarely stays quiet for long. It starts as sensitivity, then becomes the kind of pain that wakes people at 2 a.m., ruins meals, and makes the whole side of the face feel tender. By the time someone searches for an Emergency Dentist, the problem has usually moved beyond a simple cavity. The decay may have reached the inner nerve, weakened the remaining tooth structure, or triggered infection in the gums, bone, or surrounding tissues.

That change matters. Early decay can often be handled with a straightforward filling during a routine appointment. Severe decay is different. The dentist has to make several decisions quickly. Can the tooth still be saved? Is there active infection? Has the crown of the tooth broken down too much to support a restoration? Is the pain coming from nerve inflammation, an abscess, a cracked wall of the tooth, or food packed into a deep cavity? Emergency treatment is not just about stopping pain for the next few hours. It is about stabilizing the mouth, protecting overall health, and choosing the path that gives the patient the best long-term result.

In practice, two patients can walk in with similar pain and leave with very different treatment plans. One may need an urgent filling and medication for inflammation. Another may need a root canal the same day. A third may be beyond saving and require extraction. The right option depends on how much healthy tooth remains, where the decay sits, whether the nerve is alive or dying, and whether swelling or drainage suggests infection has spread.

When tooth decay becomes a dental emergency

Not every cavity needs same-day care, but severe decay often does. The tipping point is usually pain, swelling, or loss of function. If a person cannot chew, sleep, or concentrate because of the tooth, it has crossed into emergency territory. The same is true when there is facial swelling, a bad taste from drainage, fever, or difficulty opening the mouth.

Dentists also worry about how fast the situation can worsen. A decayed molar with a large hole may trap food and bacteria deep under the gumline. Pressure builds. The nerve inside the tooth may become irreversibly inflamed, then die. Once the pulp becomes infected, bacteria can escape through the root tip into the surrounding bone. That is when a patient may notice throbbing pain, tenderness to biting, or swelling in the gum that looks like a pimple.

Children, older adults, and people with diabetes or immune compromise can decline faster than expected. Someone who has waited months with a broken-down tooth may feel surprisingly little pain at first because the nerve has already died. Then the infection flares, often suddenly. That pattern catches many people off guard.

A few signs should push a person to call an Emergency Dentist promptly:

- Severe, constant toothache that does not settle with rest or over-the-counter pain relief
- Swelling of the gum, jaw, or face near the decayed tooth
- A bad taste, pus drainage, or foul odor coming from the area
- Pain when biting, especially if the tooth feels high or loose
- Fever, swollen glands, or trouble opening the mouth

Those symptoms do not always mean the same treatment is needed, but they do mean the tooth should be evaluated without delay.

What the emergency visit usually involves

People often imagine emergency dental care as a rushed extraction, but that is not how good emergency treatment works. The first goal is diagnosis. A skilled clinician looks at the tooth, checks for swelling, percussion tenderness, mobility, deep gum pockets, and visible fracture lines. X-rays help show how far the decay extends and whether the infection has reached the root or bone. Cold testing or electric pulp testing may be used to judge nerve vitality, though those tests are less useful in some heavily decayed teeth.

That first exam is also where judgement matters. A tooth can look terrible and still be restorable. The reverse is true too. I have seen molars with dramatic surface cavities save beautifully with endodontic treatment and a crown. I have also seen front teeth with modest-looking decay prove hopeless because the cavity wrapped under the gum and left no ferrule, meaning not enough solid tooth above the gumline to support a lasting crown.

Pain control starts early. Local anesthetic is often enough, though infected lower molars can be stubbornly difficult to numb. In those cases, experienced dentists may use supplemental injections in the ligament space or inside the pulp chamber if the tooth is already opened. The appointment may end with definitive treatment, or with a stabilizing procedure that gets the patient comfortable and safe until a longer visit can Emergency Dentist be arranged.

Emergency fillings when decay is deep but the tooth is still stable

One of the more favorable scenarios is severe decay that has not yet irreversibly damaged the nerve. The patient may have sensitivity to cold or sweets, food packing, and intermittent pain, but not lingering spontaneous throbbing. If enough tooth structure remains and the decay can be cleaned out completely, the dentist may place a filling, often with a protective liner near the nerve.

This sounds simple, but the decision is not casual. Deep decay removal carries a risk of exposing the pulp. In some cases, the dentist intentionally removes decay in stages, especially when the decay is extremely close to the nerve and immediate full excavation could turn a salvageable tooth into a root canal case. Temporary materials may be used first, with re-evaluation later once the tooth has settled.

That conservative approach can work very well, particularly in younger teeth with better healing potential. The trade-off is uncertainty. A tooth that seems calm on the day of treatment may still declare itself later with lingering pain, meaning the nerve was already too inflamed to recover. Patients should know that a deep emergency filling can be both the correct first step and not necessarily the final one.

Pulp capping and partial pulp therapy in select cases

When decay is removed and the pulp is just barely exposed, a dentist may consider direct pulp capping or partial pulp therapy. These are tooth-saving procedures aimed at preserving the vitality of the nerve rather than removing it. They are more common in younger patients and in situations where the exposure is small, the area can be kept clean and dry, and the symptoms suggest the pulp is still capable of healing.

Modern bioceramic materials have improved the predictability of these procedures, but they are not magic. They work best in carefully chosen teeth. If the patient came in with severe spontaneous pain that lingers for minutes after hot or cold, the pulp is more likely irreversibly inflamed. In that setting, capping the nerve is usually wishful thinking rather than sound treatment. The key point is that emergency dentists are not just drilling and filling. They are balancing short-term relief with biological reality.

Root canal treatment when the nerve is infected or dying

For many patients with severe tooth decay, root canal treatment is the most effective way to stop pain and save the tooth. This becomes the leading option when the decay has entered the pulp and caused irreversible pulpitis or pulp necrosis. Clinically, that often looks like intense lingering sensitivity to hot or cold, throbbing pain, tenderness to biting, or a tooth that now hurts more from pressure than temperature because the nerve has died and the surrounding tissues are inflamed.

The emergency phase of root canal care can happen in one of two ways. If time and conditions allow, the dentist may complete the full root canal that day. More often in a true emergency schedule, the dentist opens the tooth, removes infected tissue from the chamber, begins cleaning the canals, and places medication inside before sealing the tooth temporarily. Even that partial treatment can dramatically reduce pressure and pain.

Patients sometimes assume the decay caused the pain only because food was stuck in a hole. Once the dentist enters the tooth, the extent of disease becomes clearer. A molar with one large visible cavity may also have hidden undermined walls and bacterial contamination extending well into the roots. That is why a root canal is not simply a deeper filling. It is a disinfection procedure followed by structural rebuilding.

After emergency root canal therapy, the next step matters just as much as the first. Most back teeth that have lost a lot of structure from decay need a crown. Without one, they are far more likely to fracture. A common real-world problem is a patient who feels better after the emergency visit, postpones the crown for months, then returns with a split tooth that can no longer be saved. Relief is not the same as completion.

Temporary sedative dressings and staged treatment

Sometimes definitive treatment is not possible at the first visit. The patient may have limited time, severe swelling, difficulty **pediatric emergency dentist** getting numb, or financial constraints. In those cases, a dentist may place a sedative temporary restoration after removing soft infected decay. This can reduce sensitivity, keep food out, and buy time for a planned filling, root canal, or extraction.

This option is useful, but it should be understood for what it is: temporary stabilization. A sedative material can calm an inflamed tooth, yet it does not reverse advanced decay. Temporary fillings also wear down, leak, or break if left too long. They are not a substitute for comprehensive care. The best emergency dentists are clear about that, because false reassurance leads to bigger problems later.

Drainage and infection management

When swelling is present, the treatment plan changes. Dentists are trained to look for the source and path of infection. If there is a localized abscess, opening the tooth or making a small incision in the gum may allow drainage. That can provide rapid relief by reducing pressure. In many cases, drainage is more useful than antibiotics alone.

Antibiotics have a role, but not for every painful cavity. If the infection is confined within the tooth and there is no swelling, no fever, and no spreading cellulitis, antibiotics may add little benefit. They do not remove decay and they do not sterilize a dead pulp. Overprescribing them creates side effects and resistance without solving the problem. On the other hand, when infection is spreading, facial swelling is visible, lymph nodes are enlarged, or the patient is medically vulnerable, antibiotics become an important adjunct to local treatment.

This is one of the areas where emergency dental judgement has to be sharp. Too little treatment leaves the infection active. Too much reliance on medication delays the real fix. The best outcomes come from addressing the source mechanically, whether that means opening the tooth, draining the abscess, or extracting the tooth if it cannot be restored.

Tooth extraction when the tooth cannot be saved

Not every severely decayed tooth is a candidate for restoration. If the decay extends too far below the gumline, if there is not enough remaining structure for a crown, if the tooth is cracked vertically, or if bone support is too poor, extraction may be the most responsible option. That can be hard to hear, especially if the patient has endured pain hoping the tooth could still be rescued.

Extraction is often the fastest way to eliminate an active source of infection and pain, but it comes with consequences. Losing a molar changes chewing patterns. Adjacent teeth can drift. Opposing teeth may over-erupt. Replacing the tooth later with an implant, bridge, or partial denture adds cost and complexity. Saving a restorable tooth is usually preferable when the prognosis is sound. Extracting a hopeless one is equally important when repeated procedures would only postpone failure.

Emergency extraction can be straightforward or difficult. Severely decayed crowns sometimes crumble during removal, leaving roots that need surgical elevation. Active infection can make anesthesia less predictable, especially in lower back teeth. Patients often do better when they understand that a difficult extraction does not mean something went wrong. It reflects the condition of the tooth at the time care was finally sought.

What happens after the emergency treatment

The immediate aftercare depends on the procedure, but the broader message is the same. Severe decay is usually a sign that more than one issue is present. Even if only one tooth hurts, nearby teeth may have smaller lesions, leaking restorations, or early gum disease. An emergency visit puts out the fire. It should lead into a complete plan.

For patients, the first 48 hours are about reducing irritation and watching for warning signs. Soft foods help. Biting on the treated side should be avoided if a temporary filling is in place. Pain that gradually decreases is expected. Pain that intensifies, swelling that worsens, or a fever that appears after treatment deserves a call back.

A practical home care approach before and after the visit usually includes:

- Rinsing gently with warm salt water if the gum is irritated
- Taking only the pain medication recommended by the dental team or listed on the label
- Avoiding very hot, very cold, sticky, or sugary foods around the tooth

- Keeping the area as clean as possible with careful brushing
- Returning promptly for the permanent restoration or follow-up visit

That last point is where many emergency cases succeed or fail. The crisis ends, the calendar fills up, and the patient delays the next step. Temporary work fails, untreated neighboring decay progresses, and the cycle starts again.

Cost, timing, and why the cheapest first step is not always cheapest overall

Money often shapes emergency dental decisions, and ignoring that reality does not help anyone. A sedative filling costs less than a root canal and crown. An extraction may cost less upfront than saving the tooth. But the least expensive visit is not always the least expensive outcome.

Take a lower first molar in a healthy adult. If it is restorable, a root canal and crown may cost more now, but keeping that tooth may prevent years of shifting bite forces, food trapping, and replacement costs. In contrast, spending on repeated temporary patches for a tooth with almost no structure left can become the most expensive path because failure is built in from the start.

A good Emergency Dentist explains the options in plain language, including likely lifespan and risks. There is no single right answer for every patient. A college student with a badly broken wisdom tooth may reasonably choose extraction. A middle-aged patient with a strategic chewing tooth and healthy surrounding bone may be better served by saving it. Context matters.

Edge cases that change the treatment plan

Some situations make severe decay more complicated than it appears on an X-ray. Pregnancy, blood thinners, bisphosphonate use, uncontrolled diabetes, recent radiation to the jaws, and heart conditions requiring special consideration can all influence timing and technique. So can severe dental anxiety. A patient who has avoided care for years may not tolerate a long root canal visit during an acute pain episode. In those cases, staged treatment or sedation can make the difference between partial care and effective care.

Children present a different set of choices. A severely decayed baby tooth may still need urgent treatment if pain or infection is present, but the options can include pulpotomy, stainless steel crown, or extraction depending on the child’s age and how close the permanent tooth is to erupting. The goal is not just to stop pain, but to protect speech, nutrition, and space for adult teeth.

Front teeth also deserve special mention. People are often highly motivated to save them for cosmetic reasons, and sometimes they can be saved even when decay is extensive. But decay that runs deep below the gum in the front can create difficult restorative margins and long-term gum problems. Occasionally, extraction followed by a well-planned replacement gives a cleaner result than heroic attempts to retain a compromised tooth.

Choosing the right emergency provider

When pain is severe, most people want the first available appointment, and that is understandable. Still, provider choice matters. An emergency dentist who can take diagnostic radiographs, manage infection, perform root canal access, and discuss extraction versus restoration offers a much broader safety net than a clinic limited to basic palliative care.

Experience shows in the details. It shows when the dentist distinguishes reversible sensitivity from a failing nerve. It shows when they know a swollen lower molar may need both drainage and close follow-up. It shows when they do not promise to save every tooth, but also do not remove one that could have had a solid future with proper treatment. That kind of judgement is what patients are really seeking when they search for an Emergency Dentist, even if they think they are just looking for pain relief.

The bigger lesson behind severe tooth decay

Severe decay is often the endpoint of a long process rather than a sudden event. A missed recall, an old filling that leaked quietly, dry mouth from medication, night snacking, reflux, grinding, or simply postponing a small problem until life calmed down, all of it adds up. By the time emergency care is needed, the tooth has usually been under stress for months or years.

That should not be read as blame. People delay care for all kinds of reasons, including cost, fear, work schedules, caregiving responsibilities, and past bad experiences. The important thing is what happens next. Once the acute pain is controlled and the emergency treatment is done, the focus should shift to prevention and completion. High-fluoride toothpaste, diet review, regular exams, protective restorations, and managing dry mouth can make a dramatic difference, especially for patients who have just learned the hard way how fast decay can escalate.

The best emergency treatment options for severe tooth decay are the ones that match the actual condition of the tooth, not the ones that merely postpone the next crisis. Sometimes that means a deep filling. Sometimes it means root canal treatment. Sometimes it means extraction and a plan to replace the tooth wisely. The emergency matters, but the long-term judgement behind it matters more.

Smyle Dental Bakersfield
2016 E St, Bakersfield, CA 93301, United States
+16614939040

FAQ About Emergency Dentist

What counts as a dental emergency?

Severe tooth pain, facial swelling, uncontrolled bleeding, a knocked-out or displaced tooth, and significant dental trauma may need prompt assessment. Trouble breathing or rapidly increasing swelling requires urgent medical help.

What should I do if a permanent tooth is knocked out?

Handle the tooth by the crown rather than the root, keep it moist, and contact a dentist immediately. Fast treatment can improve the chance of saving the tooth.

Can an emergency dentist treat severe tooth pain the same day?

Same-day care may be available depending on the cause and schedule. The dentist will examine the area, may take digital X-rays, and recommend treatment based on the diagnosis.

Should I go to the emergency room for dental swelling?

Seek urgent medical care for trouble breathing, difficulty swallowing, rapidly spreading facial swelling, or other severe symptoms. A dentist can assess the underlying dental cause and provide appropriate follow-up care.