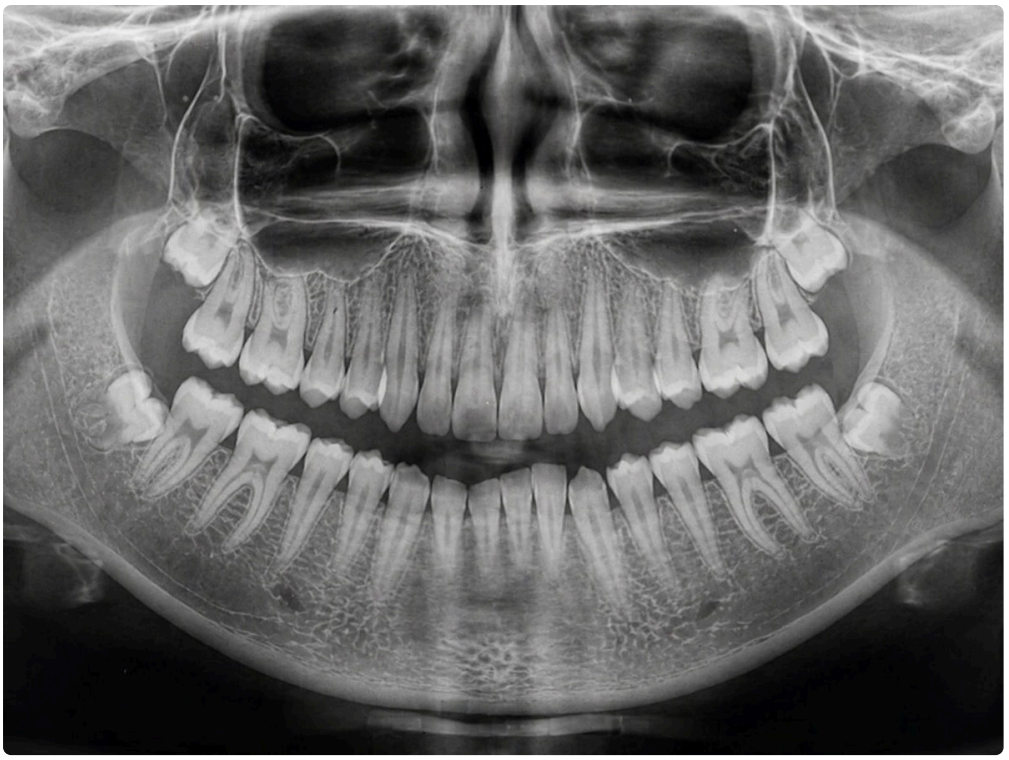

The most honest answer is that there is no single perfect birthday for wisdom teeth removal. There is, however, a window when removal is often easier, healing is usually smoother, and the long-term risk of complications tends to be lower. For many patients, that window falls in the late teens to early twenties, often around ages 17 to 25.

That range gets repeated for a reason, but it is not a rule that fits everybody. I have seen 16-year-olds who clearly needed treatment because their third molars were trapped, painful, and starting to damage neighboring teeth. I have also seen adults in their thirties and forties who kept symptom-free wisdom teeth for years and never needed surgery. The right timing depends less on age alone and more on anatomy, symptoms, tooth position, oral hygiene, and what a panoramic X-ray or 3D scan shows.

If you are trying to decide whether now is the right time, it helps to understand why dentists and oral surgeons talk so much about timing, what changes as the body gets older, and when watchful waiting makes sense.

Why wisdom teeth create so many timing questions

Wisdom teeth, also called third molars, are the last teeth to develop and usually the last to erupt. Most people have up to four, one in each back corner of the mouth, though some have fewer and some never develop them at all. Their late arrival is part of the problem. By the time they begin trying to erupt, usually sometime in the late teens or early twenties, the jaw may not have enough room to accommodate them.

When there is not enough space, wisdom teeth can come in sideways, partially erupt, stay trapped under the gum or bone, or press against the second molars in front of them. That is where the trouble starts. Food and bacteria collect easily around a partially erupted tooth. Gums become inflamed. Decay can begin in places that are hard to clean. Sometimes the patient feels obvious pain. Other times the damage develops quietly and only shows up on imaging.

This is why age matters, but not in the simplistic sense of younger is always better. What matters is the stage of development. A developing wisdom tooth with roots that are not fully formed is often easier to remove than a fully developed tooth whose roots are long, curved, or wrapped near the nerve in the lower jaw. Younger bone is also generally less dense and more forgiving during healing. Those are practical surgical considerations, not sales language.

The age range most surgeons consider favorable

For many patients, the sweet spot for Wisdom Teeth Removal is somewhere between 17 and 25. In that period, several things often work in the patient's favor.

The roots may still be forming, which can make the teeth less firmly anchored. The surrounding bone is usually somewhat softer than it will be later in life. Healing capacity is typically strong. Swelling and stiffness can still happen, of course, but younger patients often bounce back faster. A college student may need a long weekend and a few quieter days. A healthy 38-year-old can also recover well, but the surgery may be more involved and the postoperative course less predictable.

There is another reason clinicians favor that age range. It is often the point when potential problems become visible before they become severe. An X-ray might show a lower wisdom tooth leaning forward into the second molar. The Wisdom Teeth Removal Oxnard Dentistry patient may not have pain yet, but the risk is easy to see. In that situation, removing the tooth before decay, gum damage, or root resorption develops can spare the patient a bigger problem later.

That said, favorable does not mean mandatory. A symptom-free 19-year-old with fully erupted, easy-to-clean wisdom teeth that fit well in the mouth may not need extraction simply because of age.

What changes after the mid-twenties

Wisdom teeth can still be removed safely later in life, and many are. The issue is not that surgery suddenly becomes dangerous after 25. The issue is that certain risks and challenges tend to increase gradually with age.

As roots fully form, they may become longer, more curved, or closer to the inferior alveolar nerve in the lower jaw. Bone becomes denser. Teeth can be more firmly embedded. Healing may take a little longer. Dry socket,

prolonged swelling, jaw stiffness, and delayed recovery can become somewhat more common, though these outcomes still vary widely from person to person.

Adults also tend to accumulate more dental history. Fillings, crowns, previous orthodontic work, gum recession, clenching habits, and early bone loss can all shape the decision. A 42-year-old with a partially erupted lower wisdom tooth that keeps flaring up and trapping food often has a clearer reason for removal than an 18-year-old whose wisdom teeth are merely present on an X-ray.

I often tell patients that age is a modifier, not the diagnosis. It influences how easy or difficult removal may be, but it does not decide by itself whether removal is necessary.

When earlier removal often makes sense

Some situations argue strongly for earlier treatment, even when the patient is still in the teen years. If a wisdom tooth is causing repeated inflammation of the gum flap around it, known as pericoronitis, waiting can mean more pain, more antibiotics, and more disruption. If a lower wisdom tooth is pressing against the second molar, it may create a cavity on the back side of that tooth, which is one of the most awkward places to restore. Saving a healthy second molar is usually a higher priority than preserving a problematic wisdom tooth.

Earlier removal can also make sense for orthodontic reasons in selected cases. It is important to be precise here. Wisdom teeth do not automatically cause crowding in the front teeth, despite how often that myth gets repeated. But if an orthodontist or oral surgeon sees a poorly positioned third molar threatening the neighboring tooth or compromising long-term stability in a crowded arch, extraction may be part of a broader treatment plan.

Athletes, students, and patients with demanding schedules sometimes choose planned removal during a relatively calm period rather than waiting for an emergency during exams, travel, military training, or a work deadline. That kind of timing is practical, not cosmetic. A painful flare-up rarely arrives at a convenient moment.

When waiting is reasonable

Not every wisdom tooth needs to come out. This point deserves more attention than it usually gets. Some wisdom teeth erupt normally, function reasonably well, and remain healthy for years. Others stay buried in bone and never create disease. In those cases, monitoring can be appropriate.

A reasonable watch-and-wait approach usually depends on careful follow-up. The teeth should be clinically assessable or radiographically visible enough to monitor changes. The surrounding gum tissue should be healthy. There should be no signs of decay on the wisdom tooth or the second molar, no cystic changes, no repeated infections, and no evidence that the tooth is resorbing the neighbor’s root or compromising the jawbone.

This is where real-world judgment matters. Patients often hear two extreme messages. One is, “Take them all out early, no questions asked.” The other is, “If they do not hurt, leave them alone forever.” Both are too simplistic. Some silent wisdom teeth are harmless. Some silent wisdom teeth are quietly damaging the tooth in front of them. Pain is not a reliable screening tool.

Signs that the timing may be right now

A patient does not need to wait until misery sets in. There are several common signs that push the balance toward extraction:

- repeated gum swelling or infection around a partially erupted wisdom tooth
- decay in the wisdom tooth or on the back of the second molar

- food trapping that cannot be controlled with normal cleaning
- cystic change, bone loss, or root damage seen on imaging
- lack of space with a position that makes future trouble likely

Outside of those scenarios, the decision gets more individualized. One patient may have mild intermittent soreness once or twice a year and opt for removal before it worsens. Another may have impacted teeth that have not changed in a decade and prefer surveillance with periodic imaging. Both choices can be reasonable when guided by examination findings.

The anatomy matters more than the calendar

A 20-year-old and a 30-year-old can have completely different levels of complexity. One of the biggest drivers of decision-making is the position of the tooth. A fully erupted upper wisdom tooth with straightforward roots can be easier to remove at 35 than a deeply impacted lower wisdom tooth at 18. Lower third molars, especially those angled forward or lying horizontally, often create the trickiest cases.

Relationship to the nerve is especially important for lower wisdom teeth. If a panoramic X-ray suggests the roots are very close to the inferior alveolar nerve, a 3D cone beam scan may be recommended. That does not mean something is wrong. It means the surgeon wants a clearer map before planning the procedure. In some cases, the information confirms that routine extraction is appropriate. In others, it changes the surgical plan or informs a more detailed discussion of nerve-related risk.

Upper wisdom teeth have their own considerations, including proximity to the maxillary sinus. Again, this is not usually dramatic, but it matters in surgical planning and postoperative expectations.

What teenagers and parents should know

Parents often ask whether a child should have wisdom teeth removed preemptively before college. Sometimes yes, sometimes no. The best approach is not to tie the decision to a school calendar alone. A teenager should first have a proper evaluation with imaging. At 15 or 16, it may still be too early to know exactly how the teeth will erupt. At 17 or 18, the picture is usually clearer.

If removal is advised, it is fair to ask why now rather than later. A solid answer should be specific. The surgeon should be able to point to concrete reasons such as unfavorable angulation, recurrent infections, damage risk to adjacent teeth, lack of space, or a developmental stage that offers a cleaner surgical window. “Because everyone gets them out” is not a good enough reason on its own.

Teenagers also tend to recover well, but they still need realistic preparation. Swelling usually peaks after the first day or two. The mouth may feel stiff. Eating can be annoying. A patient who expects to be back to normal in 24 hours may feel alarmed by a perfectly ordinary recovery. Good preparation helps more than bravado.

Adults who kept their wisdom teeth for years

Adults often feel uneasy when a dentist suddenly recommends wisdom teeth removal after years of being told nothing. Sometimes that recommendation is overdue. Sometimes it reflects a genuine change. Gum recession around a partially erupted tooth, a new cavity on the second molar, or a change seen on imaging can shift the balance.

I have seen many adults who tolerated intermittent gum irritation for years and finally chose extraction after a second molar developed a cavity in a spot that was almost impossible to clean or restore properly. They often say

the same thing after recovery: they wish they had dealt with it sooner, not because the surgery was terrible, but because the chronic nuisance had become normal to them.

I have also seen the opposite. Adults with deeply embedded, stable wisdom teeth and no sign of disease may go decades without issue. In those cases, monitoring is not neglect. It is an informed decision.

The trade-offs patients should weigh

Any surgery has costs and benefits. Wisdom Teeth Removal is common, but common does not mean trivial. Time off work or school, swelling, soreness, cost, and the small but real risk of complications all deserve respect. So do the potential consequences of waiting.

Patients usually make better choices when the trade-offs are discussed plainly:

- removing a problematic tooth earlier may reduce future damage to nearby teeth and can simplify surgery
- removing a tooth that might never cause harm exposes the patient to a procedure they may not have needed
- waiting avoids immediate surgery but may allow decay, infection, or harder extraction later
- a healthy, functional wisdom tooth can sometimes be kept, provided it is truly cleanable and monitored
- the best decision often changes as new symptoms or imaging findings appear

That kind of balance is more useful than blanket advice. Dentistry works best when it is specific.

Recovery expectations by age

Younger patients often heal faster, but “faster” is relative. Most people, regardless of age, should expect several days of noticeable recovery and a couple of weeks before the area feels mostly settled. Soft tissue closes before deeper bone remodeling finishes, so the site may feel odd for longer than it looks.

Older patients are not doomed to rough recoveries. Many do very well, especially when the extraction is straightforward and they are healthy non-smokers who follow instructions carefully. But statistically and practically, age can increase complexity. That is why many surgeons prefer not to postpone clearly indicated extractions without reason.

Smoking, vaping, certain medications, diabetes, immune conditions, and oral hygiene habits can influence healing as much as age does. A fit 34-year-old with excellent health may recover more smoothly than a sleep-deprived 19-year-old who smokes and ignores instructions.

Questions worth asking before deciding

A useful consultation should leave you with a clear sense of whether the recommendation is preventive, urgent, or optional. Ask what the X-ray shows. Ask whether the tooth is damaged now or simply likely to cause future trouble. Ask how close the roots appear to the nerve or sinus. Ask what changes if you wait one year, three years, or five years.

You should also ask whether all wisdom teeth need the same plan. It is common for one or two to be obvious extraction candidates while another can be monitored. Teeth do not have to be treated as a package deal just because they are all called wisdom teeth.

If the recommendation is to watch them, ask how often they should be reevaluated and what symptoms should prompt earlier review. Monitoring only works if there is a plan.

So, what age is ideal?

For many people, the ideal age falls in the late teens to early twenties, not because that age is magically correct, but because it often aligns with favorable root development, easier surgery, and smoother healing. If a wisdom tooth is poorly positioned, repeatedly infected, damaging the next tooth, or clearly headed toward trouble, that age range often offers the cleanest opportunity to act.

But ideal timing is not measured by age alone. The best time is when the evidence supports treatment and before avoidable damage occurs. For one patient, that is 17. For another, it is 29. For another, it may be never.

The smartest next step is not to chase a number. It is to get a careful exam, review the imaging, and make a decision based on your anatomy, your symptoms, and the likely path those teeth are taking. That is what turns a common procedure into good judgment.

Oxnard Dentistry
1730 E Gonzales Rd, Oxnard, CA 93036, United States
+1 805-307-8731

FAQ About Wisdom Teeth Removal

How painful is it to remove a wisdom tooth?

Local anesthetic numbs the area during extraction. Pressure may still be noticeable; tell the dentist if you feel pain. Soreness and swelling afterward are common. Follow the pain-control instructions provided for your situation.

How long is recovery for wisdom teeth extractions?

Recovery varies with the tooth position and complexity of the extraction. Some people resume routine activities quickly, while others need several days of rest. Soreness, swelling and jaw stiffness can last up to two weeks.

Follow your clinician's aftercare and activity advice.

What are the risks of wisdom tooth removal?

Possible complications include dry socket, infection, persistent bleeding and changes in sensation from nearby nerve injury. Your dentist or oral surgeon should explain your individual risks before treatment. Seek prompt dental advice for bleeding that will not stop, fever, or severe or worsening pain and swelling.